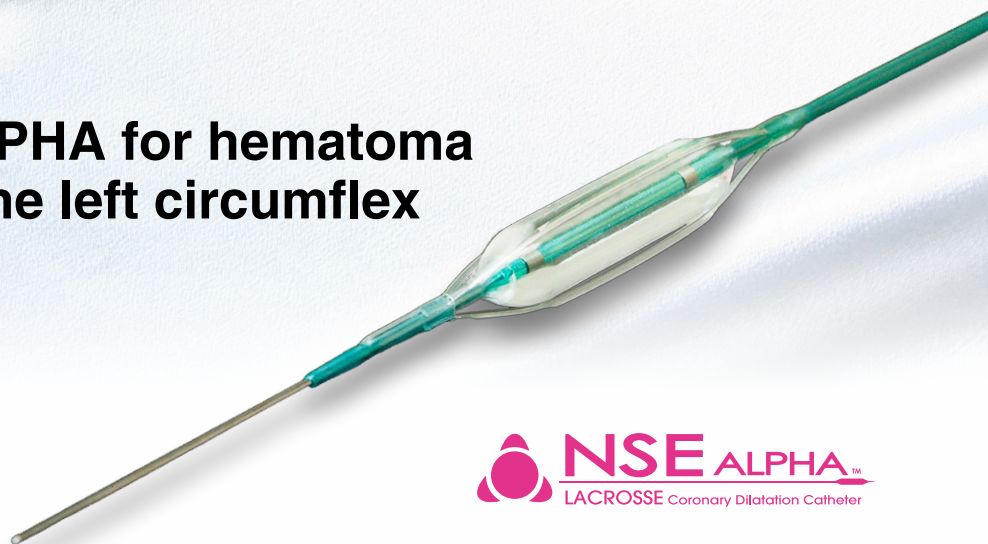

## Case Report

# Efficacy of NSE ALPHA for hematoma post treatment of the left circumflex



Higashi Takarazuka  
Sato Hospital  
Department of Cardiology  
Dr. Shin Takiuchi

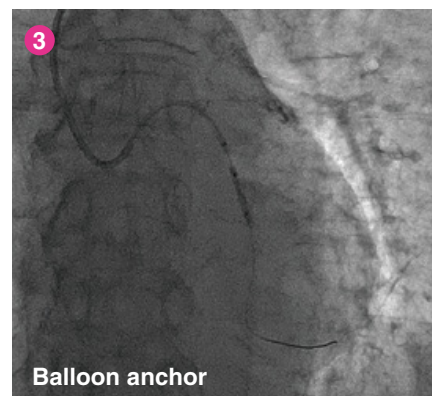
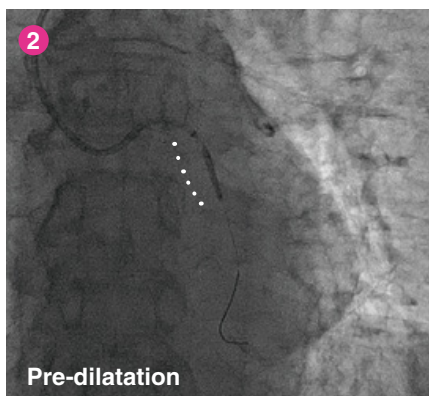
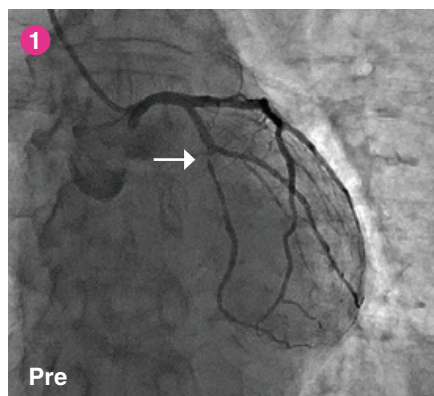


**NSE ALPHA™**  
LACROSSE Coronary Dilatation Catheter

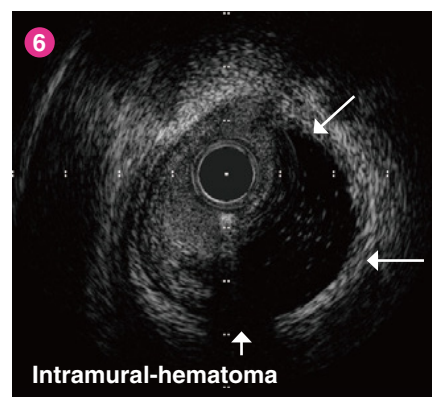
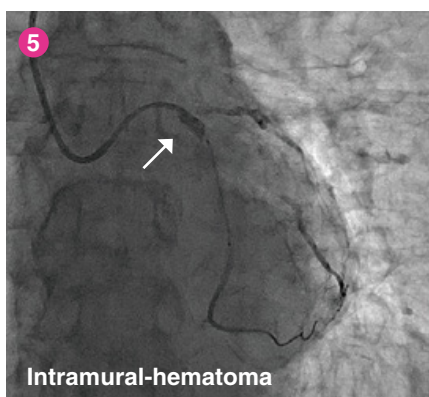
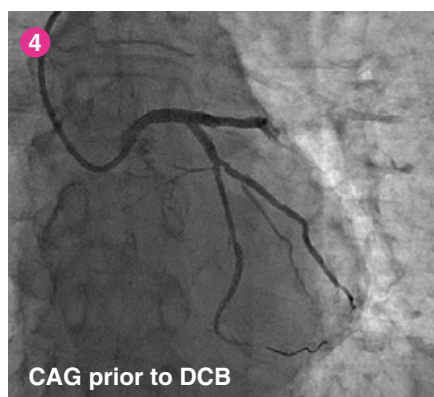
## Case 81 year old male

- ▶ Silent myocardial ischemia
- ▶ A stenosis at LCX was indicated by coronary CT and CAG during a thorough examination prior to a lung cancer procedure. Anti-platelet therapy was commenced post-procedure, and the patient was hospitalized for the treatment of the LCX.
- ▶ Target lesion : LCX Mid. 90% ①
- ▶ Guiding catheter: 6F JL4.0
- ▶ Approach: Rt. Radial

A wire was crossed to the mid LCX. The lesion was evaluated using IVUS, however due to insufficient guiding catheter back-up support, a strategy of PCI utilizing a guide extension catheter (GUIDEPLUS) was determined. A 2.25x13mm NSE ALPHA ② was selected for lesion pre-dilatation, although GUIDEPLUS delivery using a balloon anchor incurred significant resistance and failed to cross the lesion ③.

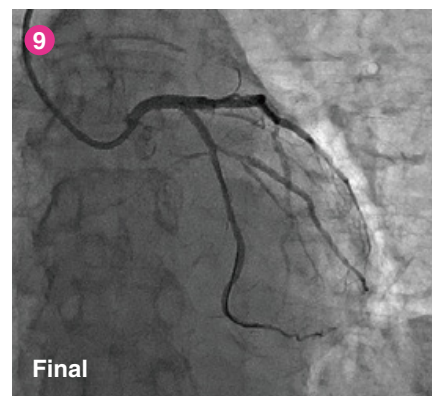
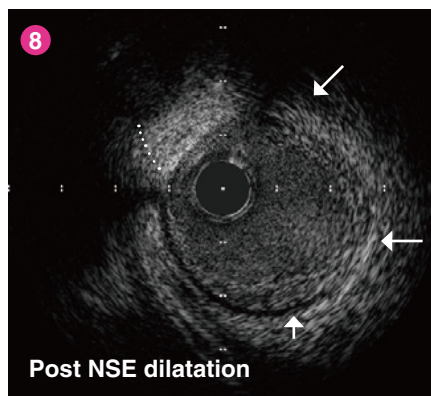
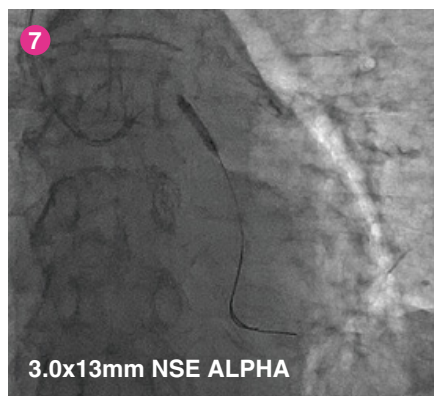


With the GUIDEPLUS left in place, an angiogram was performed from the guiding catheter ④, and a DCB was selected to treat the lesion. A DCB (SeQuent® Please 2.5x30mm) was delivered under GUIDEPLUS support, and another angiogram was performed to confirm the position prior to dilatation. An accumulation of the contrast medium was observed in the proximal LCX ⑤. The lesion was dilated with a DCB at 7atm, and IVUS confirmed an intramural-hematoma ⑥.



A 3.0x13mm NSE ALPHA was delivered to the intramural-hematoma using a 2 wire technique, and the hematoma portion was dilated 7. The size of the NSE was based on the vessel diameter evaluated by IVUS.

The NSE ALPHA successfully created a re-entry point into the hematoma. The intramural-hematoma completely dissipated 8, and after a 10 minute wait, the final angiogram confirmed an improved blood flow of the LCX and the procedure was completed 9.



### Physician's comment

- ▶ It has been reported that IVUS evaluated intramural-hematoma is a complication which occurs in 6.7% of PCI.\* While there are cases in which the intramural-hematoma is naturally absorbed, in other cases it could progress either acutely or chronically, potentially causing a fatal myocardial infarction. Therefore it is necessary to perform a bail out strategy.
- ▶ For the treatment of intramural-hematoma, stent implantation is effective for temporarily maintaining blood flow and for restraining the progress of dissections. However, it may cause an extension of the hematoma, and in the long term it could potentially lead to late stent mal-apposition as the hematoma becomes absorbed, potentially causing late re-stenosis or late in-stent thrombotic occlusion.
- ▶ In this case, the NSE ALPHA successfully created a re-entry point reducing pressure, and the bail-out was successful. Although Cutting Balloon may also be effective, NSE ALPHA can be considered even more effective for the treatment of intramural-hematoma due to the crossability of the device.
- ▶ When an iatrogenic intramural-hematoma is observed such as with this case, it is crucial to quickly evaluate the scope of the hematoma and determine appropriate balloon sizing by IVUS, as well as avoid unnecessary contrast medium injection.

#### Reference

Maehara A et al. Circulation 105;2:37-42,2002